

# Interventional Radiology Treatments for Liver Cancer

For inoperable liver tumours, radiofrequency ablation (RFA) offers a non-surgical, localised treatment that kills the tumour cells with heat, while sparing the healthy liver tissue. Thus, this treatment is much easier on the patient than systemic therapy. Radiofrequency energy can be given without affecting the patient's overall health and most people can resume their usual activities in a few days.

In this procedure, the interventional radiologist guides a small electrode through the skin into the tumour under CT scan or ultrasound guidance. Then, a mild radiofrequency energy (similar to microwaves) is transmitted to the tip of the needle, where it is converted into heat. The heated electrode results in a precise focal area of tumour destruction with very little risk of damaging adjacent normal structures. The dead tumour tissue shrinks and slowly forms a scar .

## References

1. Solbiati L, Livraghi T, Goldberg SN, et al. Percutaneous radiofrequency ablation of hepatic metastases from colorectal cancer: long-term results in 117 patients. *Radiology* 2001;221:159-166.
2. de Baere T, Elias D, Dromain C, et al. Radiofrequency ablation of 100 hepatic metastases with a mean follow-up of more than 1 year. *AJR* 2000;175:1619-1625.
3. Seidenfeld J, Kom A, Aronson N. Radiofrequency ablation of unresectable primary liver cancer. *J Am Coll Surg* 2002;194:813-828.
4. Farrell MA, Charboneau WJ, DiMarco DS, Chow GK, Zincke H, Callstrom MR, Lewis BD, Lee RA, Reading CC. Imaging-guided radiofrequency ablation of solid renal tumors. *AJR Am J Roentgenol*. 2003 Jun;180(6):1509-13.
5. Gervais DA, McGovern FJ, ArcUano RS, McDougal WS, Mueller PR. Renal cell carcinoma: clinical experience and technical success with radio-frequency ablation of 42 tumors. *Radiology*. 2003 Feb;226(2):417-24.
6. Wood BJ, Abraham J, Hvizda JL, Alexander HR, Fojo T. Radiofrequency ablation of adrenal tumors and adrenocortical carcinoma metastases. *Cancer*. 2003 Feb 1 ;97(3):554-60.
7. Callstrom MR, Charboneau JW, Goetz MP, Rubin J, Beres R, Regge D. Percutaneous CT/US-guided radiofrequency ablation of painful metastases involving bone: a multicenter study. *Radiology* 2002;225(P):163. (abstract, full publication in *J Clin Oncol* 2003 in press).
8. Gervais DA, Arellano RS, Mueller PR. Percutaneous radiofrequency ablation of nodal metastases. *Cardiovasc Intervent Radiol*. 2002 Nov-Dec;25(6):547-9.
9. Callstrom MR, Charboneau JW, Goetz MP, Rubin J, Wong GY, Sloan JA, Novotny PJ, Lewis BD, Welch TJ, Farrell MA, Maus TP, Lee RA, Reading CC, Petersen IA, Pickett DD. Painful metastases involving bone: feasibility of percutaneous CT- and US-guided radio-frequency ablation. *Radiology*. 2002 Jul;224(1):87-97.



## SERVICE IS AVAILABLE AT:

**Radiology Department, Gleneagles Hospital**  
6A Napier Road Singapore 258500  
Tel: (65) 6470 5740/1 Fax: (65) 6470 5749

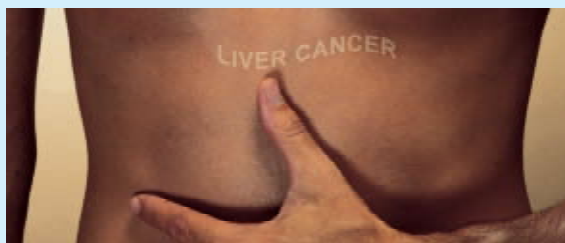
**Radiology Department, Mount Elizabeth Hospital**  
3 Mount Elizabeth  
Singapore 228510  
Tel: (65) 6731 2100 Fax: (65) 6732 3368

[www.imagingservices.com.sg](http://www.imagingservices.com.sg)

BUSINESS REG NO 32871800M

# Radiofrequency Ablation & Chemoembolisation



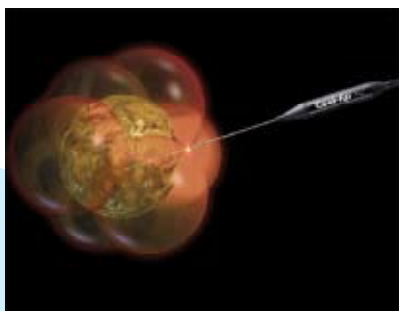


## Radiofrequency Ablation

For inoperable liver tumours, radiofrequency ablation (RFA) offers a non-surgical, localised treatment that kills the tumour cells with heat, while sparing the healthy liver tissue. Thus, this treatment is much easier on the patient than systemic therapy. Radiofrequency energy can be given without affecting the patient's overall health and most people can resume their usual activities in a few days.

In this procedure, the interventional radiologist guides a small electrode through the skin into the tumour under CT scan or ultrasound guidance. Then, a mild radiofrequency energy (similar to microwaves) is transmitted to the tip of the needle, where it is converted into heat. The heated electrode results in a precise focal area of tumour destruction with very little risk of damaging adjacent normal structures. The dead tumour tissue shrinks and slowly forms a scar.

**Radiofrequency ablation (RFA) offers a non-surgical, localised treatment that kills the tumour cells with heat, while sparing the healthy liver tissue.**



## Efficacy

Depending on the size of the tumour, RFA can shrink or kill the tumour, extending the patient's survival time and greatly improving their quality of life while living with cancer. For small tumours, RFA has results similar to surgery. For larger tumours, its use may be palliative. Because it is a local treatment that does not harm healthy tissue, the treatment can be repeated as often as needed to keep patients comfortable. It is a very safe procedure, with complication rates on the order of 2% to 3%, and has been available since the late 1990s.

By decreasing the size of a large mass, or treating new tumours in the liver as they arise, the pain and other debilitating symptoms caused by the tumours are relieved. While the tumours themselves may not be painful, when they press against nerves or interfere with vital organs, they can cause pain. RFA is effective for small to medium-sized tumours and emerging new technologies should allow the treatment of larger cancers in the future.



## Chemoembolisation

Chemoembolisation is another minimally invasive treatment for liver cancer. Chemoembolisation can be used when there is too much tumour to treat with RFA, when the tumour is in a location that cannot be treated with RFA, or in combination with RFA or other treatments.

Chemoembolisation delivers a high dose of cancer killing drug (chemotherapy) directly to the organ while depriving the tumour of its blood supply by blocking, or embolising, the arteries feeding the tumour.

Using imaging for guidance, the interventional radiologist threads a tiny catheter up the femoral artery in the groin into the blood vessels supplying the liver tumour.

The embolic agents keep the chemotherapy drug in the tumour by blocking the flow to other areas of the body. This allows for a higher dose of chemotherapy drug to be used, because less of the drug is able to circulate to the healthy cells in the body. Chemoembolisation usually involves a hospital stay of two to four days. Patients typically have lower than normal energy levels for about a month afterwards.

**Chemoembolisation is a palliative, not a curative, treatment. It can be extremely effective in treating primary liver cancers, especially when combined with other therapies. Chemoembolisation has shown promising early results with some types or metastatic tumours.**

Advances in interventional radiology make it possible to kill tumour cells without harming the surrounding tissue. Two procedures, tumour ablation and chemoembolisation, offer hope for patients whose tumours are inoperable. Using their skill in imaging to guide a needle through the skin and into the tumour. Interventional Radiologists apply heat to kill the tumour. These doctors also deliver a high dose of cancer-killing drug directly to the site while depriving the tumour of its blood supply. Tumour ablation and chemoembolisation are just two of many minimally invasive, targeted treatments offered by Interventional Radiologists.

Know your options. Today you have non-surgical choices and direct access to these specialists.